



Therapeutic Effect of Autologous Platelet Rich Plasma on Persistent Epithelial Defect due to Infectious Keratitis

Jirotiya V*

Department of Ophthalmology, Railway Hospital Ajmer, India

*Corresponding author: Vaibhav Jirotiya, Department of Ophthalmology, Railway Hospital Ajmer, 4/42 Pooja Marg, Dhola Bhata, Ajmer, Rajasthan, India, Tel: 9571169019; Email: vjvjannat@gmail.com

Received Date: August 22, 2024; Published Date: September 05, 2024

Abstract

Purpose: Platelet-rich plasma (PRP), also known as autologous conditioned plasma, is a concentrated source of platelet-rich proteins obtained from whole blood through centrifugation, which removes red blood cells. This study aims to evaluate the effectiveness of PRP in treating persistent corneal epithelial defects.

Method: PRP eye drops were prepared and used by patient of corneal epithelial defect in post infectious corneal ulcer patients and effect was seen in terms of healing on slit lamp.

Result: PRP contains high levels of PDGF, TGF, FGF, IGF 1&2, VEGF, EDGF, and Interleukins. PRP was used in 50 patients and the healing of corneal epithelial defect was evaluated.

Conclusion: PRP is found to be efficacious in healing of corneal epithelial defect in post infectious corneal ulcer patients with minimal side effects.

Keywords: Corneal; Platelet; Plasma

Abbreviations

PRP: Platelet-Rich Plasma; IL-1: Interleukin-1; TNF- α : Tumor Necrosis Factor-Alpha; EGF: Epidermal Growth Factor; TGF- β : Transforming Growth Factor-Beta; PDGF: Platelet-Derived Growth Factor; KGF: Keratocyte Growth Factor; HGF: Hepatocyte Growth Factor; IGFs: Insulin-Like Growth Factors.

Introduction

The cornea and sclera form the outermost layer of the eye, serving as a protective coat for the internal ocular structures. The cornea, a transparent and avascular tissue, functions as both a structural barrier and a defence mechanism against

infections [1]. Positioned at the front of the eye as part of the fibrous tunic, the cornea is essential for vision, contributing significantly to the eye's refractive power [2]. Due to its constant exposure to environmental elements, the cornea is particularly susceptible to injury. As a result, corneal ulcers, which can stem from trauma, infection, or other factors, are among the most prevalent and serious ocular diseases, potentially leading to vision impairment if not properly treated [3].

When the cornea is injured, its healing process is initiated immediately by the release of cytokines such as interleukin-1 (IL-1) and tumor necrosis factor-alpha (TNF- α), along with various growth factors that support tissue repair. These cytokines trigger an inflammatory response, which is

essential for the healing process. IL-1 and TNF- α are key in attracting immune cells to the site of injury, aiding in cell migration, and stimulating the production of additional inflammatory mediators [4,5].

Growth factors like epidermal growth factor (EGF) and transforming growth factor-beta (TGF- β) are also crucial, as they promote the proliferation and migration of epithelial cells and help modulate the extracellular matrix, a process necessary for proper tissue remodeling. The synergy between these cytokines and mediators ensures that the wound healing process proceeds efficiently, ultimately restoring the cornea's clarity and function [4]. Platelet-rich plasma (PRP) is a biologically active concentrate of platelets, obtained through the centrifugation of whole blood that has been mixed with an anticoagulant. This process separates platelet-rich plasma, which is important for wound healing. Platelets play an important role in tissue repair by releasing various cytokines and growth factors to coordinate healing responses. Alpha granules in platelets release important bioactive molecules, including platelet-derived growth factor (PDGF), platelet factor IV, and transforming growth factor- β (TGF- β). Such growth factors are known to increase cell migration, proliferation, and angiogenesis, thereby promoting effective and efficient wound healing [6,7]. Due to the epitheliotropic factors in PRP, there is proliferation, migration, and differentiation of the ocular surface epithelium and facilitates healing [8,9]. Due to these properties, PRP has gained significant value as a therapeutic agent in regenerative medicine and tissue repair [10].

Platelet-rich plasma (PRP) is known to contain many biologically active substances that are also found in tears. Many factors such as epidermal growth factor (EGF), transforming growth factor-beta (TGF- β), fibronectin, and vitamin A are present in significantly higher concentrations in PRP than in natural tears. These components are critical for the proliferation, differentiation, and maintenance of corneal epithelial cells, making them particularly effective in the treatment of ocular surface disorders [11-14]. Due to these properties, serum eye drops have been effectively used for the management of ocular surface diseases, injuries, corneal ulcers, dry eyes, ocular GVHD, neurotropic keratopathies, persistent and recurrent corneal erosions and ulcers [15-23].

Material and Methods

In the present study, we evaluated the clinical records of 50 eyes of 50 patients with epithelial defect of post infectious corneal ulcer. The patients were prior treated at some other centre with proper antibacterial and antifungal medication with no signs, symptoms & findings of active infection but the epithelial defects were persisted even after 30 days or more at the end of treatment. The patients attended OPD for

complaints like ocular watering, irritation and discomfort and were diagnosed here as persistent epithelial defect under slit lamp after staining with fluorescein strip under cobalt blue filter (Figure 1).



Figure 1: Slit lamp used for assessment of epithelial defect with cobalt blue filter.

Corneal epithelial defect was examined for dimensions under slit lamp after fluorescein staining using cobalt blue filter by making horizontal and vertical slits and taking measurement from scale on the top of the slit lamp by adjusting height of slit (Figure 2).



Figure 2: Dimensions taken from scale on the slit lamp.

Inclusion Criteria

Total 50 eyes of 50 patients mean age 63 years ranging 52 - 74 years, 37 male, 13 female were included in this study who visited the OPD between April 2019 and 2020 with corneal epithelial defect were treated with autologous PRP. 15 patients were treated for fungal ulcer 22 patients for bacterial ulcer and 13 patients for mixed bacterial and fungal ulcer.

Exclusion Criteria

Patients who had some significant systemic illness like diabetes and some lid, lash abnormalities like 7th nerve palsy, entropion, trichiasis, were excluded in this study.

Preparation of Autologous PRP

20 ml of blood was used and mixed with two ml of anticoagulant-citrate-dextrose solution and centrifuged at 1200 rpm for 8 min and then 2400 rpm for 4 min. The uppermost layer and buffy coat layer were separated in a sterile manner and transferred to the empty vial of artificial eye drops. Patients were explained to store these bottles at -15 to -18°C in freezer and shift to lower row of refrigerator 30 min before use at 4°C.

A vial of drop was advised to be discarded in 5 days and to visit to hospital for PRP extraction and new vial dispensing and to visit soon if found any complaints in eye like redness, discharge or watering to rule out any contaminant in the vial provided. Frequency of instillation was explained to be 4 times a day and asked to review initially every alternate day then every 3 days then 5 days and dose was reduced as per response to QID then TID.

Results

Out of 50 patients 48 patients achieved almost complete reepithelialisation except 2 ageing 67 years due to poor compliance who landed up into infectious ulcer again with symptoms and signs of inflammation and were started with

antibacterial and antifungal injectables and eye drops but didn't resolve due to poor personal hygiene and compliance further referred to higher centre (Figure 3).

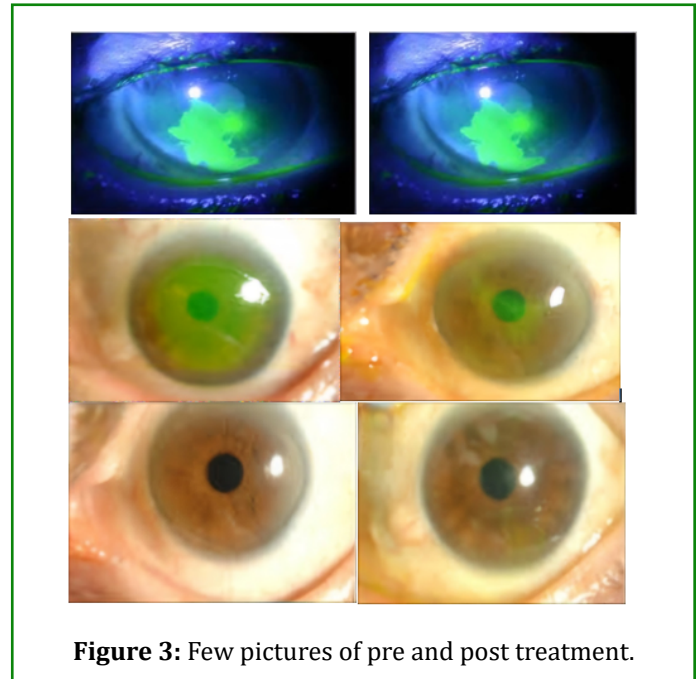


Figure 3: Few pictures of pre and post treatment.

The average horizontal dimension of corneal epithelial defect after fluorescein staining on cobalt blue filter of slit lamp was 6.25 mm ranging 4.5 - 8 mm and vertical dimension was 7 mm ranging 5 - 9 mm in the patients before PRP. Average time taken to heal the epithelial defect after PRP therapy was 14.5 days ranging 7 - 22 days (Table 1).

S. No.	Patient with Age	Horizontal Epithelial Defect Size (mm)	Vertical Epithelial Defect Size (mm)	Time Taken (days)
1	52	7	6.4	13
2	52	6.8	7.8	14
3	52	6.5	5.5	14
4	52	4.8	5.8	11
5	54	7.5	6.4	18
6	54	8	6.2	16
7	54	4.8	5.2	10
8	55	6.5	7.2	15
9	55	6.8	7.6	12
10	55	7.8	6.6	8
11	55	6.2	7.4	9
12	55	5.2	6.8	11
13	55	4.8	5.8	11
14	58	6.2	6.8	16

15	59	5.6	7.2	10
16	59	5.4	5.2	7
17	59	7.5	8.6	14
18	62	7.2	5.4	15
19	62	6.4	5.6	14
20	62	4.8	5.6	14
21	62	6.5	6.8	10
22	63	7.8	9	18
23	64	7.6	6.5	10
24	64	4.5	5.4	15
25	64	4.8	6.4	11
26	64	6.8	6.2	16
27	64	7.4	7.8	18
28	65	6.2	5	17
29	65	4.8	5.4	18
30	65	6.6	7.2	15
31	65	7.2	6.8	19
32	65	5.4	6.2	16
33	65	7.5	7.2	19
34	67	8	9	Not healed
35	67	6.8	5.5	15
36	67	7.4	8.2	22
37	67	7.2	8.4	Not healed
38	68	7.2	6.8	20
39	68	6.4	6.4	18
40	68	4.6	5.8	17
41	68	7.8	7.5	11
42	69	5.8	5.8	17
43	72	6.5	8.4	22
44	72	4.8	6.8	18
45	72	6.2	8.8	17
46	74	6.5	7.4	17
47	74	7	6.8	16
48	74	7.5	7.8	21
49	74	6.8	6.4	17
50	74	7.4	8	21

Table 1: Epithelial Defect Size.

Discussion

Epidermal growth factor (EGF) acts as a chemotactic agent for both epithelial and stromal cells, stimulates the proliferation

of limbal and peripheral epithelial cells as well as stromal fibroblasts, and encourages the production of fibronectin. Consequently, EGF stimulates the production of extracellular matrix proteins to aid in repair of corneal epithelium. Damage

to the epithelium causes the production and release of several additional growth factors and inflammatory cytokines in platelets, including interleukin-1 (IL-1) and tumour necrosis factor alpha (TNF- α). In response to IL-1, keratocytes release growth factors that affect the migration and multiplication of epithelial cells, including keratocyte growth factor (KGF) and hepatocyte growth factor (HGF). The differentiation and development of epithelial cells and stromal keratocytes are regulated by transforming growth factor beta (TGF- β) and insulin-like growth factors (IGFs). Thymosin- β 4 facilitates epithelial migration and re-epithelialization during wound healing, while platelet-derived growth factors (PDGFs) control keratocyte migration and proliferation.

Fibronectin plays an important role in wound healing process, particularly in the migration of corneal epithelial cells. During the healing process, fibronectin acts as a temporary scaffold, providing a surface over which these cells can move as they work to repair the damaged tissue. In addition to serving as this vital matrix, fibronectin also has a chemotactic property. This dual function of fibronectin-both guiding and stimulating cell movement-makes it an essential component in the healing of corneal injuries [24-26].

Conclusion

Platelet rich plasma is known to be effective modality for corneal epithelial defect treatment with least side effects.

References

- Whitcher JP, Srinivasan M, Upadhyay MP (2001) Corneal blindness: a global perspective. *Bull World Health Organ* 79(3): 214-221.
- Sridhar MS (2018) Anatomy of cornea and ocular surface. *Indian J Ophthalmol* 66(2): 190-194.
- Perches CS, Brandão CV, Ranzani JJ, Rocha NM, Sereno MG, et al. (2012) Matrix metalloproteinases in corneal repair: literature review. *Vet Zootec* 19(4): 480-489.
- Sabeeh K, Mohan RR (2021) Corneal stromal wound healing: Major regulators and therapeutic targets. *The ocular surface* 19: 290-306.
- Netto MV, Ambrósio R, Chalita MR, Krueger RR, Wilson SE (2005) Corneal wound healing response following different modalities of refractive surgical procedures. *Arq Bras Oftalmol* 68(1): 140-149.
- Knighton DR, Ciresi K, Fiegel VD, Schumerth S, Butler E, et al. (1990) Stimulation of repair in chronic, nonhealing, cutaneous ulcers using platelet derived wound healing formula. *Surg Gynecol Obstet* 170(1): 56-59.
- Lynch SE, Colvin RB, Antoniadis HN (1989) Growth factors in wound healing: single and synergistic effects in partial thickness porcine skin wounds. *J Clin Invest* 84(2): 640-646.
- Liu L, Hartwig D, Harloff S, Herminghaus P, Wedel T, et al. (2005) An optimised protocol for the production of autologous serum eyedrops. *Graefes Arch Clin Exp Ophthalmol* 243(7): 706-714.
- Tsubota K, Goto E, Fujita H, Ono M, Inoue H, et al. (1999) Treatment of dry eye by autologous serum application in Sjogren's syndrome. *Br J Ophthalmol* 83(4): 390-395.
- Marx RE (2001) Platelet-rich plasma (PRP): What is PRP and what is not PRP? *Implant Dentistry* 10(4): 225-228.
- Scardovi C, De Felice GP, Gazzaniga A (1993) Epidermal growth factor in the topical treatment of traumatic corneal ulcers. *Ophthalmologica* 206(3): 119-124.
- Pastor JC, Calonge M (1992) Epidermal growth factor and corneal wound healing: a multicenter study. *Cornea* 11(4): 311-314.
- Collins MK, Perkins GR, Rodriguez-Tarduchy G, Nieto MA, López-Rivas A (1994) Growth factors as survival factors: regulation of apoptosis. *Bioessays* 16(2): 133-138.
- Spigelman AV, Deutsch TA, Sugar J (1987) Application of homologous fibronectin to persistent human corneal epithelial defects. *Cornea* 6(2): 128-130.
- Ogawa Y, Okamoto S, Mori T, Yamada M, Mashima Y, et al. (2003) Autologous serum eye drops for the treatment of severe dry eye in patients with chronic graft-versus-host disease. *Bone Marrow Transplant* 31(7): 579-583.
- Noble BA, Loh RS, MacLennan S, Pesudovs K, Reynolds A, et al. (2004) Comparison of autologous serum eye drops with conventional therapy in a randomised controlled crossover trial for ocular surface disease. *British Journal of Ophthalmology* 88(5): 647-652.
- Kojima T, Ishida R, Dogru M, Goto E, Matsumoto Y, et al. (2005) The effect of autologous serum eyedrops in the treatment of severe dry eye disease: a prospective randomized case-control study. *Am J Ophthalmol* 139(2): 242-246.
- Tananuvat N, Daniell M, Sullivan LJ, Yi Q, McKelvie P, et al. (2001) Controlled study of the use of autologous serum in dry eye patients. *Cornea* 20(8): 802-806.
- Tsubota K, Goto E, Shimmura S, Shimazaki J (1999) Treatment of persistent corneal epithelial defect by autologous serum application. *Ophthalmology* 106(10):

1984-1989.

1115-1120.

20. Poon AC, Geerling G, Dart JK, Fraenkel GE, Daniels JT (2001) Autologous serum eyedrops for dry eyes and epithelial defects: clinical and in vitro toxicity studies. *British Journal of Ophthalmology* 85(10): 1188-1192.
21. Young AL, Cheng AC, Ng HK, Cheng LL, Leung GY, et al. (2004) The use of autologous serum tears in persistent corneal epithelial defects. *Eye* 18(6): 609-614.
22. Jeng BH, Dupps WJ (2009) Autologous serum 50% eyedrops in the treatment of persistent corneal epithelial defects. *Cornea* 28(10): 1104-1108.
23. Matsumoto Y, Dogru M, Goto E, Ohashi Y, Kojima T, et al. (2004) Autologous serum application in the treatment of neurotrophic keratopathy. *Ophthalmology* 111(6): 1115-1120.
24. Nishida T, Nakagawa S, Awata T, Ohashi Y, Watanabe K, et al. (1983) Fibronectin promotes epithelial migration of cultured rabbit cornea in situ. *J Cell Biol* 97(5 Pt 1): 1653-1657.
25. Nishida T, Nakagawa S, Awata T, Nishibayashi C, Manabe R (1982) Rapid preparation of purified autologous fibronectin eyedrops from patient's plasma. *Jpn J Ophthalmol* 26(4): 416-424.
26. Nishida T, Ohashi Y, Awata T, Manabe R (1983) Fibronectin. A new therapy for corneal trophic ulcer. *Arch Ophthalmol* 101(7): 1046-1048.
27. Table - 1